

Fetiform Teratoma (Homunculus) Coexist with Intrauterine Foetus: A Case Report

Rasheed Mumini Wemimo^{1,*}, Afolayan Enoch Abiodun², Nasir Abdulrasheed Adegoke³, Odetayo Omolara Foluke⁴, Abdulmajeed Abdulrafiu Ayinde⁵

¹Department of Anatomic Pathology, Federal Medical Centre, Birnin Kudu, Nigeria

²Department of Pathology, University of Ilorin Teaching Hospital, Ilorin, Nigeria

³Department of Surgery, University of Ilorin Teaching Hospital, Ilorin, Nigeria

⁴Department of Radiology, Olabisi Onabanjo University Teaching Hospital, Sagamu, Nigeria

⁵Department of Pathology, Federal Medical Centre, Abeokuta, Nigeria

Email address:

muminirasheed265@gmail.com (R. M. Wemimo)

*Corresponding author

To cite this article:

Rasheed Mumini Wemimo, Afolayan Enoch Abiodun, Nasir Abdulrasheed Adegoke, Odetayo Omolara Foluke, Abdulmajeed Abdulrafiu Ayinde. Fetiform Teratoma (Homunculus) Coexist with Intrauterine Foetus: A Case Report. *European Journal of Clinical and Biomedical Sciences*. Vol. 8, No. 2, 2022, pp. 15-18. doi: 10.11648/j.ejcb.20220802.11

Received: January 27, 2022; **Accepted:** March 17, 2022; **Published:** March 29, 2022

Abstract: Fetiform teratoma is also known as a homunculus, a rare form of mature cystic teratoma with a good prognosis. We report a case of fetiform teratoma that coexist with a female neonate in a 27-year-old woman. She presented with 2 days history of abdominal pain and generalized body weakness of 3 days at 38 weeks gestation. On clinical examination, gravid enlarged uterus with twin foetus palpated on a transverse lie and imminent foetal distress. Emergency Ultrasound done showed twin gestation at 39 weeks +5 days. The patient underwent an emergency caesarean section delivered of a female baby with a foetus like mass attached to the palate of the live female baby by a stalk. The clinical diagnosis of parasitic twin gestation was made and the mass was sent for histopathological analysis. On gross examination, a skin bearing mass with 2 limbs buds reminiscent of homunculus without demonstrable vertebrae or bony tissue on cross-section. Histopathology analysis showed tumour tissue composed of haphazard arrangement mature tissue comprising derivative from ectoderm namely skin tissue, sebaceous gland, hair follicle, mesodermal derivative are cartilage and adipose tissue. Endodermal differentiation is intestinal glands lined by columnar epithelial cells admixed with goblets cells. In summary, a diagnosis of fetiform teratoma was made and the baby that coexisted with the mass was adequately follow-up without any complications.

Keywords: Fetiform Teratoma, Homunculus, Foetus in Foetus

1. Introduction

Teratoma is a neoplasm with divergent differentiation from more than one germ cell layer comprising of ectodermal, mesodermal and or endodermal derivatives. It can affect any part of the body such as the ovary, testis, retroperitoneum anterior mediastinum, lumbar region and sacrococcygeal region. However, an ovary is the most commonly reported site of teratoma. The majority of teratoma arose from the ovary and are predominantly benign. A few of the ovarian teratoma are classified as monodermal and immature malignant teratoma. Sacrococcygeal teratoma is categorized as classical type,

fetiform and malignant which are predominantly found in neonates and infants. A rare type of teratoma with a high degree of differentiation reminiscent of a malformed fetus is also known as fetiform teratoma (homunculus). [1] This teratoma should be differentiated from the foetus in the foetus which is an enclosed malformed foetus with demonstrable vertebrae and parasitic twin gestation. There is diagnostic overlap with using ultrasound and clinical skills which must be confirmed with histopathological analysis.

Mature ovarian cystic teratomas are common benign ovarian neoplasm derived from germ cells. Histologically, they are composed of variable proportions of tissue arising from the

ectoderm, mesoderm, and endoderm. Fetiform teratoma (homunculus) is a term that has been given to a rare form of teratoma which resembles a foetus. [1] There is a paucity of data on reported cases in the literature. This tumour is commonly seen in women of active reproductive years but can occur in any age group and may be seen in postmenopausal women. Fetiform teratoma should be distinguished from foetus fetus, twin gestation and ectopic fetiform teratoma.

2. A Case Report

This was a case of a 27-year-old woman (gravida 2, para 1) unbooked at 38 weeks gestation who was referred from a private hospital on account of 2 days history of generalized abdominal pain and 3 days history of generalized body weakness. The pain had been progressive with no known relieving or aggravating factors. There was a history of 2 episodes of vomiting consisting of recently ingested meals and low-grade intermittent fever. There was no history of trauma to the abdomen, no rhesus incompatibility, no history of herbal concoction ingestion and no signs of labour or drainage of liquor.

She had a pelvic scan at 27 weeks which revealed twin gestation. At the referral hospital, a diagnosis of the acute abdomen was entertained keeping in view of malaria in pregnancy. She was placed on intramuscular paracetamol 300g, intramuscular artemether and intravenous metronidazole but without appreciable improvement.

She was referred to the University of Ilorin Teaching Hospital after 5 hours into hospital admission owing to no significant improvement at the private hospital.

At the Accident and Emergency Unit of the U.I.T.H, she was conscious with a Glasgow coma scale of 10/15. She was not pale and not jaundiced. She was not cyanosed but was febrile with a temperature of 38.2°C. There was bilateral pedal oedema. The other vital signs were within the normal limit. Graviddly enlarged abdomen estimated to be 40. cm. Twin fetus palpated on a transverse lie. One of the fetal heartbeats was heard with a fetal heart rate of 170beat/minutes but the other was not heard. Vaginal examination revealed closed cervix OS and cervix not favourably. An urgent pelvic scan showed parasitic twin gestation at 39 weeks +5 days. Diagnosis of fetal stress in twin gestation with a transverse lie which warranted emergency caesarean section. The following investigation were done: PCV (Packed cell volume) - 28% (Mild anaemia), Electrolyte/Urea/Creatinine: Na - 135mmol/(Normal); K - 5.6mm/L (Normal); Urea -16.2mmol/L (Moderately elevated); Creatinine: 130µmol/L (Mildly elevated); and random blood sugar - 12.5mmol/L (Mildly elevated).

She had an emergency caesarean section delivered of life female foetus with a birth weight of 2.8kg and poorly formed foetus like mass weighs 2.4kg. The APGAR score of the life baby at 1 & 5 minutes were 8/10 and 10/10 respectively. The mass was submitted for histopathological diagnosis. Grossly it is a poorly formed fetus like tissue with upper limb, lower limb, & head and weighs 2.4kg and measures

15.7cm×10.3cm. Cross-section showed multicystic cavities with a scanty tuft of hair and sebum. Representative sections were submitted into tissue cassette which was subjected to tissue processing. Microscopy showed composed of a benign tumour with derivative from ectoderm comprised of skin tissue with a hair follicle and sebaceous gland while mesoderm derivative was cartilage, adipose tissue and endoderm derivative was intestinal glands. Postoperatively, the mother and female neonate were healthy and discharged for follow up.

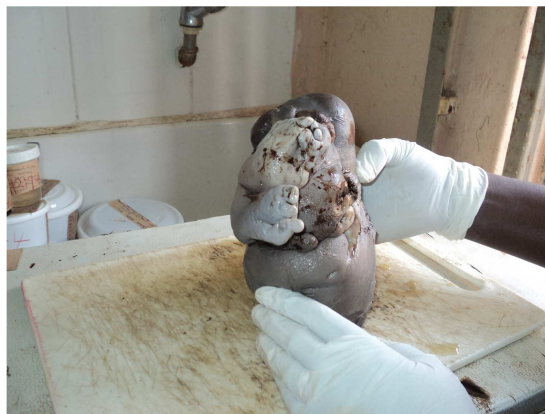

Figure 1. A skin bearing mass with poorly formed limbs, stubby digits and reminiscent of a homunculus.

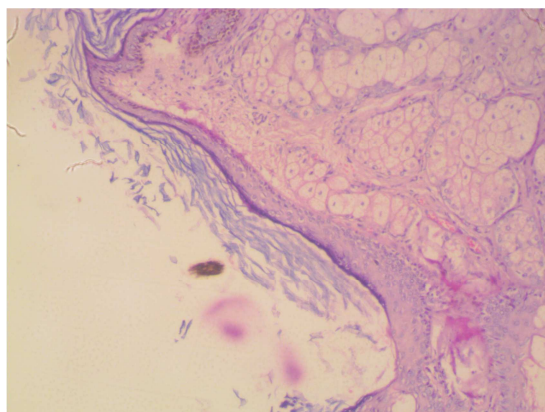


Figure 2. 2×100. The section shows ectodermal derivative comprising of skin tissue admixed with sebaceous gland.

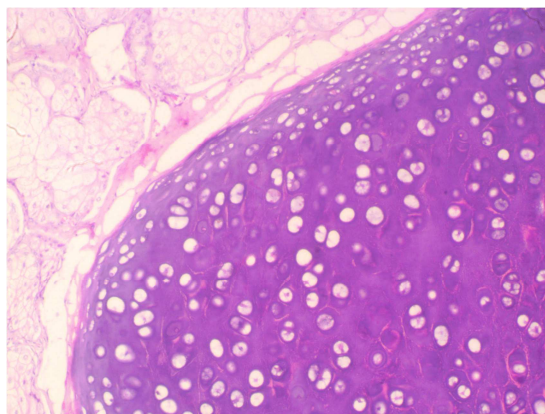


Figure 3. 3×100 Magnification. The section shows lobules of mature cartilage admixed with lobules of a sebaceous gland.

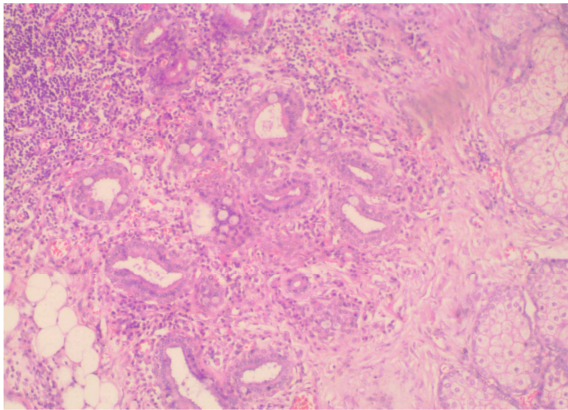


Figure 4. 4×100. The section shows tissue composed of tubular glands lined by columnar epithelial cells admixed few goblet cells reminiscent of intestinal glands.

3. Ethical Consideration

Confidentiality of the patient and record was maintained under the guidelines of the Helsinki declaration on biomedical research in human subjects.

4. Discussion

Teratoma is a tumour with a derivative from more than one germ cell layer and is also known as a dermoid cyst in clinical parlance because it almost always contains skin-like structures derivative from ectodermal origin. This tumour demonstrates a wide spectrum of differentiation from benign mature cystic or solid teratoma to malignant immature teratoma. It almost always contains mature tissue from ectodermal derivatives with differentiation from other germ cell layers such as mesoderm and endoderm. On examination, they are cystic tissue and the cross-section will contain sebum, the tuft of hair and bone tissue. A few of the cases might show poorly formed human beings known as fetiform teratoma in English literature. [1, 2].

There are few documented cases of fetiform teratoma reported in the literature which accounted for 25 cases with variable age brackets from 9 to 65 years. [1-6] In this index case, a skin bearing mass with the stump of digits was found attached to the palate of the female neonate by a stalk during the emergency caesarean section. The female neonate baby was delivered successfully with a good APGAR score while the mass was sent for analysis in the Department of Pathology, University of Ilorin Teaching Hospital, Ilorin. The specimen was submitted with a clinical impression of a parasitic twin. Surgical examination, cross-section revealed cystic cavities filled with sebum, scanty tuft of hair and solid part composed of soft to firm grey-white appearance. Microscopically, it is composed of a heterogenous disorganized arrangement of mature tissue from ectoderm namely stratified squamous epithelium, sebaceous gland, hair follicle and brain, mesodermal derivatives are mature cartilage and adipose tissue while endodermal are tubular glands lined columnar epithelial cells with few goblet cells and diagnosis

of fetiform teratoma was issued. There are a few extremely rare differential diagnoses of fetiform teratoma which are foetus in a foetus and parasitic twin gestation. [7] The theory and pathogenesis of Foetus in a foetus are usually attributed to a series of zygote cleavage between three to 8 days after fertilization which gives rise to diamniotic, monochorionic monozygotic twin that becomes incorporated into the body of the host through the anastomosis of the vitelline duct. [8-10] This particular entity was favourably ruled out during surgical cut due to the absence of vertebrae during grossing of the specimen. However, an X-ray to demonstrate vertebrae and a genetic test that would show heterozygosity in the foetus in the foetus should also be done for any suspected case. Parasitic twin gestation was ruled out owing to the absence of internal organs during surgical cut up examination of the specimen.

In summary, we have reported a case of fetiform teratoma, a rare form of a mature cystic teratoma that is well developed and organized with morphologic appearance similitude to foetus like structure. The sonologist must examine the spine whenever Ultrasound is being done for twin gestation to rule out fetiform teratoma and foetus in a foetus. It is germane to have a mobile X-ray in the hospital or Department of histopathology to demonstrate important diagnostic features or clues during surgical cut up or autopsy.

5. Conclusion

Fetiform teratoma and foetus in the foetus can confuse sonologist and clinicians which must be confirmed with histopathological analysis. This index case could have been missed if the woman was delivered in a private hospital where the priority for histopathology services are very low. Thus, contributing to under-diagnoses or poorly reported. Although not commonly found, fetiform teratoma must be considered in the differential diagnosis of a parasitic twin gestation and foetus in foetus.

Conflict of Interest Statement

There is no competing or conflict of interest.

Acknowledgements

I wish to thank the management of the University of Ilorin Teaching Hospital, Ilorin for granting me the opportunity to undergo residency training in the institution.

References

- [1] James A Greenberg, and Thomas E Clancy. Fetiform Teratoma (Homunculus). Rev Obstet Gynecol. 2008; 1 (3): 95–96.
- [2] Abbott TM, Hermann WJ, Scully RE. Ovarian fetiform teratoma (homunculus) in a 9-year-old girl. Int J Gynecol Pathol. 1984; 2: 392–402.

- [3] Kuno N, Kadomatsu K, Nakamura M, Miwa-Fukuchi T, Hirabayashi N, Ishizuka T. Mature Ovarian cystic teratoma with a highly differentiated homunculus: case report. *Birth Defects Res A Clin Mol Teratol.* 2004; 70: 40–46.
- [4] Lee YH, Kim SG, Choi SH, Kim IS, Kim SH. Ovarian mature cystic teratoma containing Homunculus: a case report. *J Korean Med Sci.* 2003; 18: 905–907.
- [5] Miyake J, Ireland K. Ovarian mature teratoma with homunculus coexisting with an Intrauterine pregnancy. *Arch Pathol Lab Med.* 1986; 110: 1192–1194.
- [6] Weldon-Linne CM, Rushovich AM. Benign ovarian cystic teratoma with homunculi. *Obstet Gynecol.* 1983; 61 (suppl 3): 88S–94S.
- [7] Brand A, Alves MC, Saraiva C, et al. Fetus in fetu: diagnostic criteria and differential diagnosis, a case report and literature review. *J Pediatr Surg.* 2004; 39: 616–618.
- [8] Thakral CL, Maji DC, Sajwani MJ. Fetus-in-fetu: a case report and review of the literature. *J Pediatr Surg.* 1998; 33: 1432–1434.
- [9] Chen CP, Chern SR, Liu FF, Jan SW, Lee HC, Sheu JC, et al. Prenatal diagnosis, pathology, and genetic study of fetus in fetus. *Prenat Diagn.* 1997; 17 (1): 13-21.
- [10] Wobenjo A, Osawa F. Fetus in Fetu: A Case Report and Review of Literature Authors. *The Annals of African Surgery.* 2010; (6): 56-59.